





Available online at  
 ScienceDirect  
www.sciencedirect.com

Elsevier Masson France  
  
www.em-consulte.com/en



ORIGINAL ARTICLE

# Vertebral body cage use in thoracolumbar fractures: Outcomes in a prospective series of 23 cases at 2 years' follow-up

N. Salas\*, R. Prébet, B. Guenoun, L.-E. Gayet, P. Pries

Orthopedics Traumatology Dept, Jean-Bernard University Hospital Center, 2, rue de la Milétrie, 86000 Poitiers, France

Accepted: 3 May 2011

## KEYWORDS

Spinal posture;  
Spinal stability;  
Vertebral body replacement;  
Minimally invasive approach

## Summary

**Introduction:** One objective of surgery in thoracolumbar spine fracture is to restore correct and lasting spinal statics. This may involve vertebral body replacement using an anterior approach. We here report results on a prospective series of 23 trauma patients managed by vertebral body replacement using an expandable cage.

**Patients and methods:** The sex ratio was 2.28. Fifteen cases involved primary treatment of recent fracture and eight secondary surgery for non-union or malunion. In 12 cases, posterior osteosynthesis was associated. Six patients were operated on using a classical approach and 17 using a video-assisted minimally invasive approach. Pre- and perioperative data were recorded, with clinical scores (VAS and Oswestry) at 6 weeks, 3 months, 6 months, 1 year and 2 years. Radiologic follow-up assessed regional traumatic kyphosis (RTK), enabling calculation of regional traumatic angulation (RTA), with control CT to check fusion.

**Results:** Minimum follow-up was 2 years. There were no cases of postoperative neurological deterioration. There were three major postoperative complications: one hemothorax, one adhesive bowel occlusion, and one bilateral pneumothorax at 1 month. Mean Oswestry score at 6 months was 20%, and mean VAS score at 2 years was 0.36. Postoperative RTA showed a mean 7.34° improvement. Mean RTA reduction loss was 1.95° at 3 months, subsequently unchanged. All arthrodeses showed fusion at 6 months.

**Conclusion:** Results were satisfactory with this technique, comparable to those reported in the literature. The development of minimally invasive approaches and improved instrumentation procedures optimize surgery and enhance anterior reconstruction tolerance. Lasting restoration of sagittal spinal curvature improves trauma patients' functional recovery.

**Level of Evidence:** Level IV. Retrospective study.

© 2011 Elsevier Masson SAS. All rights reserved.

\* Corresponding author. Tel.: +33 6 50 37 56 21.  
E-mail address: nicolaslg1@yahoo.fr (N. Salas).

## Introduction

Thirty-two years ago, Whitesides [1] wrote: "A stable spine is one that can withstand stress without progressive deformity or further neurologic damage". More recently, vertebral body fracture was defined as being unstable in case of at least one of the following five criteria: > 50% reduction in body height, Regional Traumatic Angulation (RTA) > 20°, > 50% canal narrowing, severe discoligamentary lesion, and/or neurologic deficit [2].

Primary vertebral body replacement surgery for severe traumatic vertebral fracture threatening anterior and medial spinal column stability and stasis is guided by these two definitions, and may be isolated or associated to primary posterior osteosynthesis.

Vertebral body replacement may also be indicated as a later secondary procedure in case of malunion or nonunion, deterioration or secondary onset of neurologic disorder induced by evolutive kyphosis due to mechanical deficiency in treatment by corset or posterior osteosynthesis [3–5].

The present study assessed the use of an expandable modular vertebral body cage in these two indications.

## Patient and method

This single-center prospective study recruited the first 23 patients operated on between November 2005 and December 2007: 16 male, seven female (sex ratio = 2:28); mean age, 40.5 years (range, 18–61 yrs). All were high-energy trauma victims: 10 road accidents, and 13 high-level falls. In 15 cases, surgery was primary and in eight secondary. Posterior osteosynthesis was associated in 12 cases. Preoperative plain X-ray and 3D CT was systematic, enabling fracture classification following Magerl [6].

Only one of the 23 patients had 2-level involvement (T5–T6). Fractures were mainly of the thoracolumbar junction (Fig. 1): T12 was involved in six cases, L1 in five, and L2 in four.

In 19 cases, fracture was Magerl [6] type A: four A31, two A32, nine A33 and four A2; in one case, type B3; and in three cases, type C.

Neurologic status was assessed on Frankel's classification [7]: 15 patients showed no neurologic disorder (Frankel E); one was paraplegic (Frankel A); seven had partial deficit (Frankel B, C or D).

Initial mean RTA was  $+14.2^\circ \pm 7.1^\circ$  (range,  $-7^\circ$  to  $+31^\circ$ ).

Primary vertebral body replacement was performed with a 7–10 day post-trauma interval to limit blood-loss, which is greater in case of early surgery.

Any associated posterior instability was reduced and stabilized by primary posterior osteosynthesis with a short assembly: one level above, one below. Laminectomy was performed in case of neurologic disorder.

In our initial experience, six patients were operated on using a conventional approach (thoracotomy, lumbotomy, thoracophrenolumbotomy); subsequently, a video-assisted minimally invasive approach was adopted, systematically performed by a single operator.

For levels T4 to T8, patients were installed in left lateral decubitus, and the approach was transpleural using video-assisted right mini-thoracotomy. For levels T9 to L2, patients were installed in right lateral decubitus, and the approach depended on the level: trans- or retropleural left mini-thoracotomy or retroperitoneal. For underlying levels, a retroperitoneal approach was performed on a minimally invasive left pararectal approach. All of these approaches left scars of no more than about 8 cm. Whichever the approach, fluoroscopy was integrated in the operative field, with the video monitor facing the surgeon. An inflatable cushion was placed directly under the fractured vertebra, facilitating access by inducing a temporary lateral inclination, which was induced directly at the under- and overlying intervertebral spaces when no previous osteosynthesis had been performed. At closure, the cushion was deflated, to avoid suturing under tension. In mini-thoracotomy, intubation was selective, so as to exclude the ipsilateral lung.

Vertebral body access required ligating the metameric vascular pedicle distally to the intervertebral foramen. Body release was periosteal, with possible conjoint disc opening after location under fluoroscopy.

Corpectomy was then performed by osteotome or motorized burr under visual control, taking care to conserve the contralateral cortical wall so as to protect the neighboring metameric vessels. Anterior decompression of the vertebral canal was performed when necessary by direct access to the posterior vertebral wall fragments, corpectomy then being complete.

After discectomy and superficial stripping of the adjacent vertebral plates, a modular cage filled with corticocancellous autograft material was expanded in situ using a dedicated ancillary. The modular nature of the cage optimized adaptation to the corpectomy space, associating a vertebral body of variable height and diameter to plates of various angulations.

When there was no previous posterior osteosynthesis, segmental lateral osteosynthesis was performed in the same operative step, enabling the cage to withstand the various stress patterns and also to be put under compression if need be.

For transpleural approaches, two pleural drains were fitted at closure, and the patients were held in intensive care until they were removed. Retropleural and retroperitoneal approaches required just one simple Redon® drain. Post-operative lung X-ray was performed in cases of thoracic approach, to investigate any pleural effusion.

Contraindications for the procedure were: respiratory insufficiency or any pathology precluding selective intubation, more than two adjacent fractured vertebral bodies, severe osteoporosis or lytic metastasis involving the over- and underlying levels.

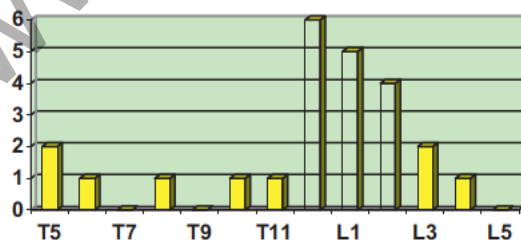


Figure 1 Fracture grade. Y-axis: number of patients.

Table 1 Perioperative results.

	Wide approach (6/23)	Minimally invasive (17/23)
Surgery time ( <i>P</i> : 0.062)	396 min (330–450)	270 min (180–370)
Blood loss ( <i>P</i> : 0.16)	1138 mL (400–2000)	1422 mL (200–5200)
Hospital stay ( <i>P</i> : 0.053)	27.83 days (10–45)	15 days (7–30)
Complications	1 bilateral pneumothorax 1 adherence occlusion	1 contralateral hemothorax

The perioperative assessment criteria were: operating time, blood loss, hospital stay, and complications (distinguishing open and minimally invasive approaches).

Follow-up clinical analysis comprised: visual analog scale (VAS) and Frankel and Oswestry scores. Radiologic analysis determined RTA; CT at 3 and 6 months checked fusion.

Follow-up was at 6 weeks, 3 months, 6 months, 1 year and 2 years.

RTK was measured on lateral X-ray views. Individual physiological kyphosis (PK) being unknown, Stagnara's values [6] were used. RTA was calculated as:  $RTA = RTK - PK$ .

Statistical analysis used SPSS software version 18 for Windows®. Results were expressed as mean  $\pm$  SD (range). Comparison of means used Student *t*-test or non-parametric Wilcoxon-Mann Whitney test for pairwise comparison of means. Correlations between paired variables were assessed by Pearson correlation coefficient. The significance threshold was set at 0.05.

## Results

Table 1 shows the perioperative results for the first six patients of the series, operated on by a classical approach, compared to the following 17, operated on by a video-assisted minimally invasive approach.

Among the first six patients, there were two complications (2 patients): one bilateral pneumothorax at 1 month, and one adherence occlusion requiring revision.

In the following 17 patients, mean blood loss was inflated by the first two cases, in which blood loss exceeded 5L; excluding these initial outliers, mean blood loss was 930 mL. One postoperative contralateral hemothorax underwent emergency revision.

There was a significant difference between the two approaches for operative time ( $P=0.062$ ) and hospital stay ( $P=0.053$ ), but not for preoperative bleeding ( $P=0.16$ ).

Minimum follow-up was 2 years.

Clinically, there was clear functional improvement over time. Mean global Oswestry score rose from 20% at 6 months to 9.4% at 2 years, and mean global VAS from 3.08/10 at 6 weeks to 0.36/10 at 2 years (Fig. 2).

Comparing approaches, patients operated on by a classical "wide" approach reported greater pain (higher VAS) than those with a minimally invasive approach, at least

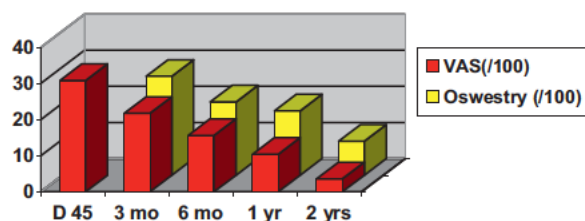
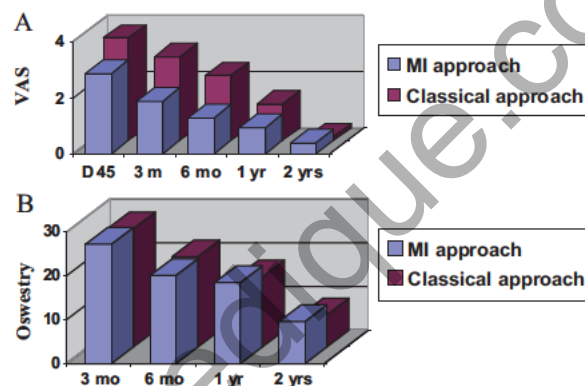


Figure 2 Functional evolution.



Figures 3 A and B: Functional scores according to approach.

during the first year; this, however, did not impair quality of life, inasmuch as Oswestry scores were similar over time in both groups (Fig. 3A and B).

Comparing primary and revision surgery, functional results at follow-up were good in both groups (VAS < 1, Oswestry score < 20%), but malunion, non-union and neurologic aggravation were associated with greater pain, with a non-negligible impact on quality of life (Fig. 4A and B).

Neurologic status showed improvement at follow-up: 19 patients were free of neurologic disorder (Frankel E) versus 15 preoperatively. However, one patient remained paraplegic (Frankel A); one was rated Frankel B and two Frankel D.

Radiologically, mean global postoperative RTA was  $6.86^\circ (\pm 6^\circ)$ :  $3.26^\circ (\pm 5^\circ)$  in primary versus  $13.62^\circ (\pm 7.94^\circ)$  in revision surgery ( $P: 0.035$ ). Mean 3-months' global correction loss was  $1.95^\circ (\pm 2.55^\circ)$ , without significant difference between primary ( $2^\circ \pm 2.66^\circ$ ) versus revision surgery ( $1.87^\circ \pm 2.34^\circ$ ) ( $P: 0.58$ ).

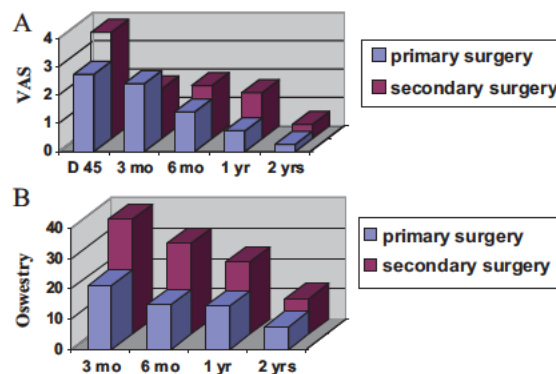


Figure 4 A and B: functional scores according to primary vs. secondary surgery.

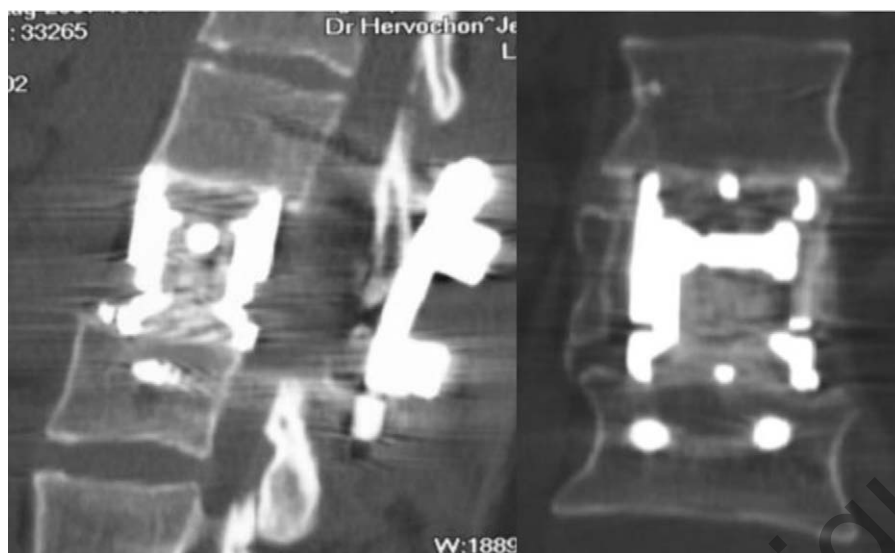


Figure 5 Arthrodesis fusion at 6 months.

Subsequently, no evolution in kyphosis was observed. CT found fusion at 6 months in all cases (Fig. 5).

## Discussion

Anatomically, ideal vertebral body fracture management would provide complete and enduring correction of vertebral kyphosis.

Some authors reported no correlation between radiologic correction of vertebral kyphosis and clinical outcome [8,9]; others found a strong correlation between residual kyphosis and poor functional results [10,11].

We consider vertebral body replacement to be indicated in major vertebral fracture threatening spinal stability and statics. The objective is to avoid evolutive kyphosis.

We therefore indicate surgery in case of any of the following five criteria: > 50% reduction in vertebral height, RTA > 20°, > 50% canal narrowing, major discoligamentary lesion, or neurologic deficit [2].

McCormack, in 1994, quantified vertebral body destruction on the score named for him [12]. He determined the

risk of posterior osteosynthesis material rupture or insufficiency, recommending anterior vertebral body replacement accordingly. He pointed out, however, that his score failed to confirm ligamentary involvement, and could therefore not provide formal indication.

Having performed primary posterior osteosynthesis in only half of the present cases, we did not use the McCormack score.

Vertebral body replacement can be 1- or 2-step. One-step surgery associates lateral osteosynthesis to vertebral body replacement in a single procedure [13,14], while 2-step surgery performs primary lateral osteosynthesis followed 5 or 6 days later by anterior replacement if step-1 control CT confirms the indications for step 2: > 50% residual vertebral height loss, RTA > 20°, and > 50% canal narrowing (Fig. 6) [15].

Posterior instrumentation can then be minimized and arthrodeses restricted to two mobile segments [16].

We argue for the 2-step attitude, as primary posterior osteosynthesis reinforces assembly stability, and enables primary RTA correction, facilitating the installation of the cage. It is especially to be recommended in primary surgery

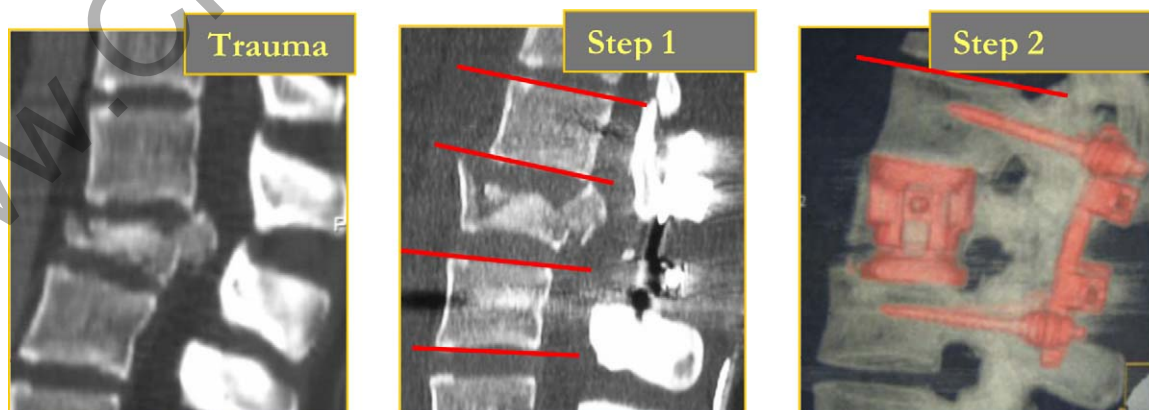


Figure 6 Two-step primary surgery. Primary posterior osteosynthesis allows initial RTA correction, facilitating cage positioning.

**Table 2** Comparison between the present and recent series.

	Ulmar et al. [27]	Knop et al. [28]	Payer [29]	Lange et al. [30]	Present series
Patients	40	50	20	38	23
FU (mo)	16.3	19.9	24		24
Surgery time (min)		144(75–275)	183 (147–247)	180 (160–530)	302 (180–450) <sup>a</sup> 270 (180–370) <sup>b</sup>
Blood-loss (mL)			640 (500–1,200)	1450	1348 (200–5200) <sup>a</sup> 1422 (200–5200) <sup>b</sup>
Hospital stay (days)				22.1	18.34 (7–45) <sup>a</sup> 15 (7–30) <sup>b</sup>
VAS at 1 yr			1.5/10		1.04/10
Postop RTA	13.8°	Correction 18.6 ± 10°	RTK: –2° (+6° to –11°)	Correction 19°	6.86 ± 6°
Correction loss	1.1°	2.1 ± 2.9°	3°	2.3 ± 3°	1.95 ± 2.5°
Consolidation		4 late 1 non-union	100%	4 late1 non-union	100%

<sup>a</sup> All 23 patients of the series.

<sup>b</sup> Minimally invasive approach only.

as emergency or late-emergency (1–5 days) corpectomy involves significant bleeding which usually requires transfusion [14,17].

Using a cage avoids the risk of secondary resorption incurred when a structural bone graft is used alone, and thus of correction loss or non-union [18]. Being expandable and modular, it adapts to the corpectomy space. It also avoids such graft-related risks as severe pain, hematoma and infection.

Minimally invasive approaches [19–25] reduce morbidity by reducing surgery time, bleeding and hospital stay and also minimizing anatomic structure lesions and functional sequelae and blemishes. However, this attitude still requires familiarity with the classical approaches in case of crossover, with help available from a vascular or thoracic surgeon. The peroperative complication risks are in fact the same: vascular lesions (aorta, cavus vein and metameric vessels, with risk of medullary ischemia in case of ligation of the artery of Adamkiewicz, due to terminal bone-marrow vascularization). There also may be neurologic lesions of intra- or extracanal structures, and lesions of epidural vessels, pulmonary parenchyma or digestive organs. The risks of secondary diaphragm hernia or pleural effusion, however, are less than on classical approaches [20].

Minimally invasive approaches also involve a learning curve. This was clear in our own experience, with considerable blood loss (5L) in the first two procedures, due to metameric vessel wounds. Likewise, although our operating times have steadily diminished, they remain higher than those in the literature (Table 2).

Finally, we found that although minimally invasive procedures reduced pain during the first year, quality of life was unaffected, with Oswestry scores similar to those for classical approaches.

We use an enlarged work opening [26] with direct visual control of the operative site: a purely endoscopic technique would not allow installation of the cage.

The benefit provided by surgery was as in the literature [27–30] (Table 2), with very satisfactory functional

recovery (1-year VAS score < 1/10). Assessment criteria, however, vary between reports, especially as regards initial surgical kyphosis correction. For Payer, the criterion is postoperative regional kyphosis; for Knop and Lange, angular correction; and for Ulmar and ourselves, postoperative regional angulation. Although the patient's pretrauma spinal balance is unknown and RTA is no more than an attempt at assessing traumatic angulation, calculated from mean values that differ from the patient's, RTA still provides the best assessment of the deviation from physiological regional kyphosis [31].

In all series, secondary correction loss was of the order of 2°.

Only Payer reported functional results.

The present is the only report comparing postoperative RTA and functional status between primary and secondary surgery: early intervention appeared preferable to revision for malunion, non-union or neurologic aggravation of vertebral body fracture.

Finally, the ongoing development of cementoplasty holds out hope of an "economic" alternative in certain indications for anterior approaches.

## Conclusion

Vertebral body replacement by anterior expandable cage provides satisfactory clinical and radiological results in traumatic thoracic and lumbar spine fracture.

Enduring restoration of sagittal spinal curvature promotes functional recovery in trauma patients.

Minimally invasive approaches optimize the procedure, but with a definite learning curve.

## Disclosure of interest

The authors declare that they have no conflicts of interest concerning this article.

## References

- [1] Whitesides Jr TE. Traumatic kyphosis of the thoracolumbar spine. *Clin Orthop Relat Res* 1977;128:78–92.
- [2] Knop C, Lange U, Reinhold M, et al. Vertebral body replacement with Synex in combined posteroanterior surgery for treatment of thoracolumbar injuries. *Oper Orthop Traumatol* 2005;17:249–80.
- [3] Wood K, Buttermann G, Mehbod A, et al. Operative compared with nonoperative treatment of a thoracolumbar burst fracture without neurological deficit. A prospective, randomized study. *J Bone Joint Surg Am* 2003;85-A:773–81 [Erratum in: *J Bone Joint Surg Am*. 2004;86-A:1283].
- [4] Argenson C. Cals vicieux et pseudarthrose du rachis thoracolumbaire. Conférences d'enseignement de la Sofcot. Paris: Expansion Scientifique Ed; 1990, p. 205–34.
- [5] Reinhold M, Knop C, Lange U, et al. Non-operative treatment of thoracolumbar spinal fractures. Long-term clinical results over 16 years. *Unfallchirurg* 2003;106:566–76.
- [6] Magerl F, Aebi M, Gertzbein SD, Harms et al. A comprehensive classification of thoracic and lumbar injuries. *Eur Spine J* 1994;3:184–201.
- [7] Frankel HL, Hancock DO, Hyslop G. The value of postural reduction in the initial management of closed injuries of the spine with paraplegia and tetraplegia. *Paraplegia* 1969;7:179–92.
- [8] Mumford J, Weinstein JN, Spratt KF, et al. Thoracolumbar burst fractures. The clinical efficacy and outcome of nonoperative management. *Spine* 1993;18:955–70.
- [9] Shen WJ, Liu TJ, Shen YS. Nonoperative treatment versus posterior fixation for thoracolumbar junction burst fractures without neurologic deficit. *Spine* 2001;26:1038–45.
- [10] Verlaan JJ, Diekerhof CH, Buskens E, et al. Surgical treatment of traumatic fractures of the thoracic and lumbar spine: a systematic review of the literature on techniques, complications, and outcome. *Spine* 2004;29:803–14.
- [11] Freslon M, Bouaka D, Coipeau P, et al. Thoracolumbar fractures. *Rev Chir Orthop Reparatrice Appar Mot* 2008;94S:S22–35.
- [12] McCormack T, Karaikovic E, Gaines RW. The load sharing classification of spine fracture. *Spine* 1994;19:1741–4.
- [13] Kaneda K, Taneichi H, Abumi K, et al. Anterior decompression and stabilization with the Kaneda device for thoracolumbar burst fractures associated with neurological deficits. *J Bone Joint Surg Am* 1997;79:69–83.
- [14] McDonough PW, Davis R, Tribus C, et al. The management of acute thoracolumbar burst fractures with anterior corpectomy and Z-plate fixation. *Spine* 2004;29:1901–8.
- [15] Kim DH, Jahng TA, Balabhadra RS, Potulski M, et al. Thoracoscopic transdiaphragmatic approach to thoracolumbar junction fractures. *Spine J* 2004;4:317–28.
- [16] Lange U, Edeling S, Knop C, et al. Anterior vertebral body replacement with a titanium implant of adjustable height: a prospective clinical study. *Eur Spine J* 2007;16:161–72.
- [17] Carl AL, Tranmer BI, Sachs BL. Anterolateral dynamized instrumentation and fusion for unstable thoracolumbar and lumbar burst fractures. *Spine* 1997;22:686–90.
- [18] Pflugmacher R, Schleicher P, Schaefer J, et al. Biomechanical comparison of expandable cages for vertebral body replacement in the thoracolumbar spine. *Spine* 2004;29:1413–9.
- [19] McAfee PC. Complications of anterior approaches to the thoracolumbar spine. Emphasis on Kaneda instrumentation. *Clin Orthop Relat Res* 1994;306:110–9.
- [20] Mack MJ, Regan JJ, McAfee PC, et al. Video-assisted thoracic surgery for the anterior approach to the thoracic spine. *Ann Thorac Surg* 1995;59:1100–6.
- [21] Baulot E, Trouilloud P, Ragois P, et al. Anterior spinal fusion by thoracoscopy. A non-traumatic technique. *Rev Chir Orthop Reparatrice Appar Mot* 1997;83:203–9.
- [22] Lazennec JY, Pouzet B, Ramare S, et al. Anatomic basis of minimal anterior extraperitoneal approach to the lumbar spine. *Surg Radiol Anat* 1999;21:7–15.
- [23] De Peretti F, Hovorka I, Argenson I. Retroperitoneoscopic anterior approach to the L2, L3, L4 vertebral bodies. *Rev Chir Orthop Reparatrice Appar Mot* 1999;85:183–8.
- [24] Hovorka I, de Peretti F, Damon F, et al. Videoscopic retropleural and retroperitoneal approach to the thoracolumbar junction of the spine. *Rev Chir Orthop Reparatrice Appar Mot* 2001;87:73–8.
- [25] McAfee PC, Regan JR, Zdeblick T, et al. The incidence of complication in endoscopic anterior thoracolumbar spinal reconstructive surgery. *Spine* 1995;20:1624–32.
- [26] Huang TJ, Hsu RW, Liu HP, et al. Video-assisted thoracoscopic treatment of spinal lesions in the thoracolumbar junction. *Surg Endosc* 1997;11:1189–93.
- [27] Ulmar B, Richter M, Kelsch G, et al. Distractible vertebral body replacement for the thoracic and lumbar spine. *Acta Orthop Belg* 2005;71:467–71.
- [28] Knop C, Lange U, Reinhold M, Blauth M. Vertebral body replacement with Synex in combined posteroanterior surgery for treatment of thoracolumbar injuries. *Oper Orthop Traumatol* 2005;3:249–80.
- [29] Payer M. Unstable burst fracture of the thoracolumbar junction: treatment by posterior bisegmental correction/fixation and staged anterior corpectomy and titanium cage implantation. *Acta Neurochir* 2006;148:299–306.
- [30] Lange U, Edeling S, Knop C, Bastian L, Oeser M, Krettek C, et al. Anterior vertebral body replacement with a titanium implant of adjustable height: a prospective clinical study. *Eur Spine J* 2007;16(2):161–72.
- [31] Stagnara P, De Mauroy J, Dran G, et al. Reciprocal angulation of vertebral bodies in a sagittal plane approach to references for evaluation of kyphosis and lordosis. *Spine* 1982;7:335–42.